

Effects of functional orthodontic appliances in the correction of a primary anterior crossbite—changes in craniofacial morphology and tongue position

Kieko Onodera^{*,**}, Naoko Niikuni^{*,**}, Munemitsu Yanagisawa^{*} and Ichiro Nakajima^{*,**}

^{*}Department of Pediatric Dentistry and ^{**}Division of Oral and Craniomaxillofacial Research, Dental Research Center, Nihon University School of Dentistry, Tokyo, Japan

SUMMARY Chin caps have been used for the correction of primary anterior crossbites, but previous studies of the treatment effects have highlighted problems such as pressure on the temporomandibular joint (TMJ). Therefore, to reduce pressure on the TMJ, a functional orthodontic appliance, the Yanagisawa Class III (YC3) shield was developed to improve the overjet in the primary dentition. The aim of this study was to determine the treatment effects of the YC3 in correcting a primary anterior crossbite compared with a chin cap.

The pre- and post-treatment lateral cephalograms of 10 patients (5 male, 5 females) and 10 treated with a YC3 (5 males, 5 females) were compared in relation to craniofacial morphology and tongue position [the YC3 was used from 51 months of age \pm 7 months to 74 months of age \pm 12 months (i.e. for 23 \pm 9 months) and the chin cap from 53 months of age \pm 2 months to 75 months of age \pm 1 month (i.e. for 22 \pm 5 months)]. A Mann–Whitney *U*-test was used to determine any statistical differences.

The YC3 group showed significantly higher values for gonial angle and U1 to SN ($P < 0.05$), and significantly lower values for interincisal and tongue position ($P < 0.05$), compared with the chin cap group. The results indicate that the use of the YC3 not only improves overjet, but also changes the tongue position. The findings also suggest that the YC3 results in functional effects on the skeletal system during the mid-growth period.

Introduction

The incidence of an anterior crossbite during the primary dentition period is 4.5 per cent in Japan (Ichiishi *et al.*, 1997). Patients with an anterior crossbite in the primary dentition are classified into two groups: subjects in whom the overjet spontaneously normalizes during the mixed dentition period, and those in whom the occlusal relationship proceeds to a reversed skeletal occlusion. Primary anterior crossbites are not only hereditary, but also reject functional disorders of the tongue and an imbalance in the muscle pressure of the lips and the tongue (Rogers, 1918; Eifert, 1960; Bandy, 1969; Moss, 1975; Yanagisawa, 1985; Adamidis and Spyropoulos, 1992; Lo, 2001).

There have been reports that the tongue occupies a lower and more anterior position in subjects with a primary anterior crossbite than in those with a normal occlusion; the abnormal tongue position being a cause of the anterior crossbite of the maxillo-mandibular anterior teeth (Yanagisawa, 1985; Uchiyama, 2000; Sakata, 2001). When an anterior crossbite remains untreated, it may result, with growth, in a skeletal type anterior crossbite. Therefore, in the early period before completion of growth, it is clinically important to maintain the balance of the jaw relationship, normal muscle function, and normal growth and

development. This can be achieved by improving a primary anterior crossbite using the mutual relationship between morphological and functional changes.

Generally, chin caps are used to treat primary anterior crossbites. The use of chin caps for a long period to suppress antero-inferior growth of the mandible improves the maxillo-mandibular relationship by posteriorly rotating the mandible, and decreasing the mandibular angle (Armstrong, 1961; Thilander, 1965; Lu *et al.*, 1991). However, problems with the use of chin caps, such as rebound after cessation of use, and an excess load applied to the temporomandibular joint (TMJ) have been reported (Mitani and Sakamoto, 1984; Agronin and Kokichi, 1987; Imai *et al.*, 1990). The Yanagisawa Class III (YC3) shield was developed to elevate the tongue position, which is believed to be a cause of primary anterior crossbites (Yanagisawa, 1985). The effect of the YC3 is to improve the overjet relationship and mandibular position by correcting axial tooth inclination. It uses muscular forces (tongue pressure) without applying pressure to the mandible.

Whilst there have been case reports (Yanagisawa, 1985; Ohki *et al.*, 1990) regarding the effects of overjet improvement on craniofacial morphology following use of the YC3 in paediatric subjects, the treatment effects of the YC3 have not been sufficiently compared with those of

conventional chin caps. The aim of this study was therefore to determine the effects of elevating a low tongue position on the development of craniofacial morphology in patients with a primary anterior crossbite and to quantify changes in craniofacial morphology and tongue position after treatment with either a YC3 or a chin cap.

Subjects and methods

The lateral cephalograms of 20 subjects who attended the Nihon University School of Dentistry with a positive overbite and negative overjet involving the primary anterior teeth, including the canines, were analysed before and after treatment using either a YC3 [10 patients (5 females, 5 males)] or a chin cap [10 patients (5 females, 5 males)]. The YC3 was used from 51 months of age \pm 7 months to 74 months of age \pm 12 months (i.e. for 23 \pm 9 months) and the chin cap from 53 months of age \pm 2 months to 75 months of age \pm 1 month (i.e. for 22 \pm 5 months), with no significant difference in age between the groups. During production of the cephalograms the patients were instructed not to swallow. Cephalograms in which the angle formed by the Frankfort horizontal (FH) plane and the inferior border of the film was within \pm 5 degrees were used, since the influence of head position on the position of the hyoid bone is minimal (Durgo and Brodie, 1962). Cephalograms with unclear images of the hyoid bone due to swallowing were excluded (8 pre-treatment and 10 post-treatment films).

The purpose of the study was explained to the patients and their parents and informed consent was obtained.

Measurements

To determine craniofacial morphology, the skeletal and dental patterns were measured (Figures 1–3) according to Downs (1948), Jacobson (1976), McNamara (1981a,b), and Ricketts, 1960, 1972). For tongue position, in addition to the points proposed by Ohki *et al.* (1990; Figure 4), the position of the hyoid bone and that of the dorsum of the tongue were measured.

Measurement error

All authors measured 20 films three times with a time interval between measurements of one week. Each measurement value was then averaged. The difference in the measured values did not exceed the standard deviation (SD) when all three measurements were averaged.

Statistical evaluation

The mean and SD of the measurements for pre-treatment maxillo-facial morphology and tongue position were calculated for each group. The Mann–Whitney *U*-test was used to analyse the pre- and post-treatment differences between the two groups.

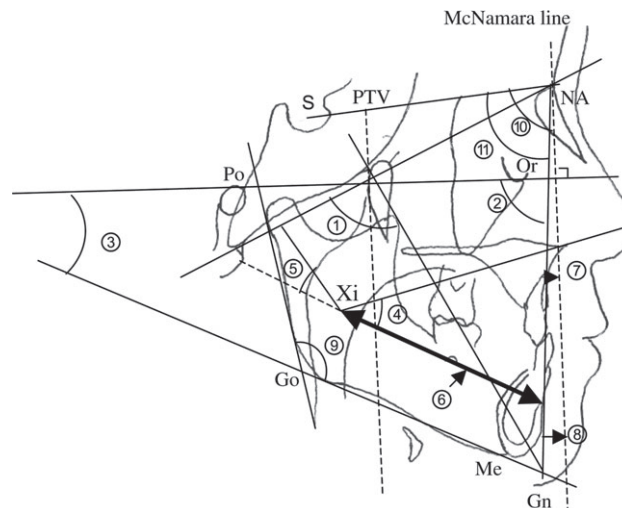


Figure 1 Measurements of craniofacial morphology. ① Facial axis: angle between the facial axis plane and the basion-nasion (BA-NA) plane; ② Facial depth: angle between the facial plane and the Frankfort horizontal (FH) plane; ③ Mandibular plane angle (MP): angle between FH plane and the mandibular plane; ④ Lower face height (LFH): angle between anterior nasal spine–Xi point (ANS–Xi) plane and the Xi point–protuberance menti (Xi–PM) plane; ⑤ Mandibular arc (MA): angle between the Xi point–protuberance menti (Xi–PM) plane and the Xi point–condyle centre (Xi–DC) plane; ⑥ Corpus length (CL): distance between the Xi point and PM point; ⑦ A to McNamara’s line (A to McNa): distance between McNamara’s line and point A; ⑧ Pogonion to McNamara’s line (Pog to McNa): distance between McNamara’s line and pogonion; ⑨ Gonial angle: angle between the MP and ramus plane; ⑩ Sella-nasion-point A (SNA): angle formed by the sella-nasion (SN) plane and the line connecting the nasion and point A; ⑪ Sella turcica-nasion-point B (SNB): angle formed by SN plane and the line connecting nasion and point A; ⑫ ANB: differences between the SNA and SNB.

Results

The measurements for craniofacial morphology and tongue position for both groups pre-treatment are shown in Tables 1 and 2. No significant differences in skeletal or dental parameters, or tongue position were found between the groups. Following treatment the values for gonial angle and U1 to SN were significantly higher in the YC3 group compared with the chin cap group; conversely the values for interincisal angle and tongue position were significantly lower ($P < 0.05$).

Discussion

It has been reported that a low tongue is a positional abnormality in subjects with an anterior crossbite in the primary dentition which influences the overjet relationship of the anterior teeth and growth of the maxillo-mandibular complex during functional movement (Rogers, 1918; Yanagisawa, 1985; Uchiyama, 2000; Sakata, 2001). The YC3 was developed to move the upper lip, facilitate anterior growth of the maxilla, and improve the tongue position by elevating it. However, no adequate evaluation of the treatment effects of the YC3 has been carried out. In this study, using lateral cephalograms, the craniofacial

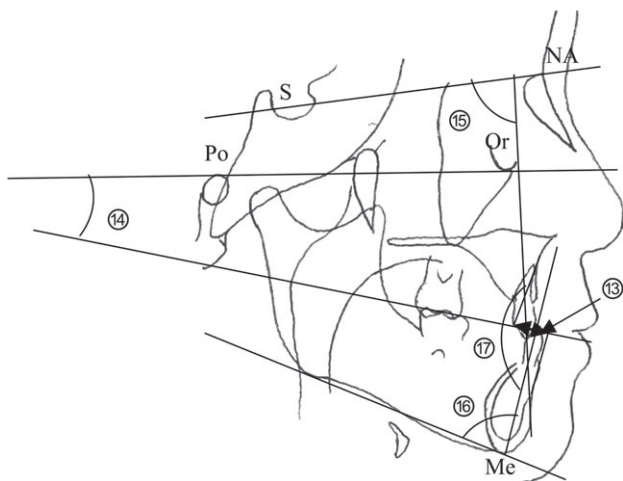


Figure 2 Measurements of craniofacial morphology. ⑬ Wits appraisal (AO-BO): a point at which a line perpendicular to the occlusal plane passing point A in the maxillary alveolar base or point B in the mandibular alveolar base crosses the occlusal plane was set as AO or BO, respectively. After measuring the distance between AO-BO, when point A was anterior to point B, the distance of AO-BO was set to positive, and when point A was posterior to point B, the distance of AO-BO was set to negative; ⑭ Cant of the occlusal plane (Occl. pl.): angle between the occlusal plane and the Frankfort horizontal plane; ⑮ Maxillary incisor inclination to the sella-nasion plane (U1 to SN): inclination angle of the maxillary central incisor tooth axis to the SN plane; ⑯ Mandibular incisor inclination to mandibular plane (L1 to Man): angle between the mandibular plane and the long axis of the mandibular central incisor; ⑰ Interincisal angle (Interincisal): angle of the line connecting the incisal edge and the root apex of the maxillo-mandibular central incisors (or the angle of the long axis of the teeth).

morphology and tongue position in subjects with a primary anterior crossbite treated with either a YC3 or a chin cap were compared pre- and post-treatment. Comparison of the craniofacial morphology and tongue position between the two groups pre-treatment showed no significant difference in craniofacial morphology or tongue position.

Comparison of the craniofacial morphology and tongue position between the groups post-treatment showed that the values for gonial angle and U1 to SN were significantly higher, while those for interincisal angle were significantly lower in the YC3 group than in the chin cap group ($P < 0.05$). For tongue position the values were significantly lower in the YC3 group than in the chin cap group ($P < 0.05$). The YC3 group showed influences on the skeletal pattern similar to those in the chin cap group, except for changes in the mandibular angle. On the other hand, the YC3 group showed both labial inclination of the maxillary anterior teeth, and significant changes in the inclination angle of the maxillo-mandibular tooth axis.

There have been reports that deficient growth of the maxilla occurs in primary anterior crossbite subjects, and that the maxillary anterior teeth are lingually inclined (Korkhaus, 1957; Higuchi, 1998). It is, therefore, suggested that the YC3 moves the upper lip and resists the force from the buccinator muscle, facilitating growth of the maxilla so that changes

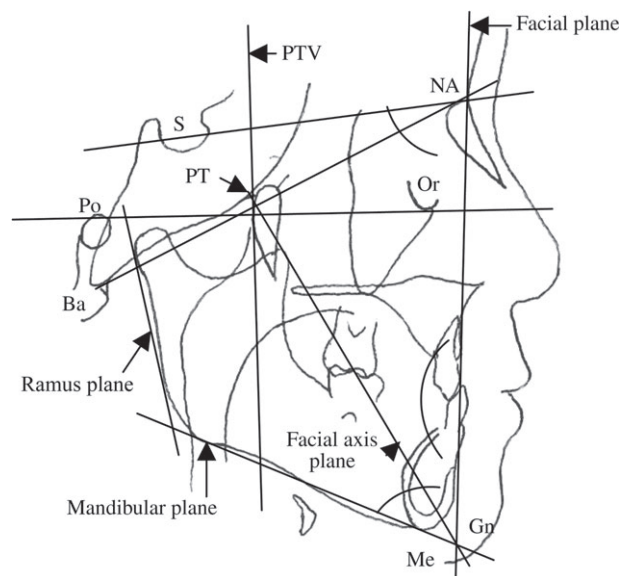


Figure 3 Landmarks and lines. *Landmarks.* Anterior nasal spine (ANS): the most anterior point at the sagittal plane on the bony hard palate; basion (BA): the most inferior posterior point of the occipital bone at the anterior margin of the occipital foramen; gnathion (GN): the intersection point of the mandibular plane and facial plane; nasion (NA): the most anterior point of the frontonasal suture; protuberance menti (PM): the point where the curvature of the anterior border of the symphysis changes from concave to convex; pterygoid point (PT): the intersection point of the inferior border of the foramen rotundum and the posterior wall of the pterygomaxillary fissure; sella: the centre of the pituitary fossa of the sphenoid bone; Xi point: a point located at the centre of the ramus. The location of Xi is keyed geometrically to the Frankfort horizontal (FH) plane and the pterygoid root vertical plane (PTV) in four steps: (1) planes are constructed perpendicular to the FH plane and PTV; (2) these constructed planes are tangent to points (R1, R2, R3 and R4) on the borders of the ramus; (3) the constructed planes form a rectangle enclosing the ramus; (4) the Xi point is located at the centre of the rectangle at the intersection of diagonals. *Lines.* Facial axis plane: a line connecting the PT and GN points; facial plane: a line connecting NA and pog points; FH plane. A line connecting the porion (Po) and orbit (Or) points; L1: the mandibular incisor line; mandibular plane: a tangent line to the lower border of the mandible; PTV: a line perpendicular to the FH plane through PT; ramus plane: a tangent line on the posterior contour of the ramus; U1: the maxillary incisor line.

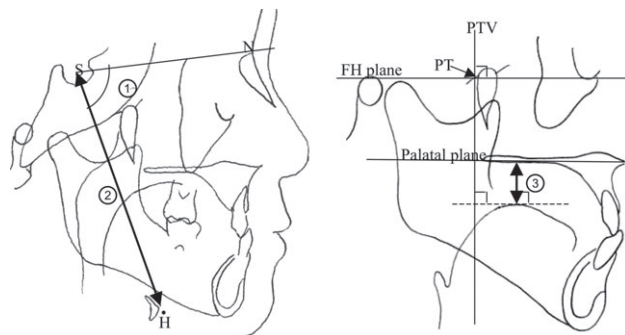


Figure 4 Measurements of tongue position. ① NSH: angle between the sella-nasion plane and the line connecting the sella point and point H (most anterior-superior point of the body of the hyoid bone); ② S-H: distance between the sella point and point H; ③ tongue position (T-P): minimum length of the line between the superior margin of the dorsum of the tongue and the palatal plane, parallel to PTV (plane vertical to the FH plane, forming a point of contact at the posterior margin of the pterygo-palatine fossa).

Table 1 Mean values and standard deviations (SD) of craniofacial morphology and tongue position in each group pre-treatment, and the results of the test of significant differences between the two groups.

| Measurements | YC3 group pre-treatment | | Chin cap group pre-treatment | | P value |
|---------------------------------|-------------------------|---------|------------------------------|--------|---------|
| | Mean | SD | Mean | SD | |
| <i>Skeletal pattern</i> | | | | | |
| Facial axis (°) | 87.89 | (2.00) | 89.35 | (3.06) | n.s. |
| Facial depth (°) | 84.67 | (1.96) | 86.16 | (1.83) | n.s. |
| Mandibular plane angle (°) | 28.48 | (3.66) | 27.55 | (3.59) | n.s. |
| Lower face height (°) | 45.17 | (3.77) | 44.81 | (3.35) | n.s. |
| Mandibular arc (°) | 30.75 | (3.82) | 33.01 | (6.07) | n.s. |
| Corpus length (mm) | 56.39 | (3.13) | 58.83 | (2.97) | n.s. |
| Point A to McNamara line (mm) | -1.28 | (2.53) | 0.65 | (2.90) | n.s. |
| Pogonion to McNamara line (mm) | -8.10 | (2.80) | -6.20 | (2.69) | n.s. |
| Gonial angle (°) | 135.25 | (3.73) | 129.02 | (5.12) | n.s. |
| SNA (°) | 81.77 | (4.07) | 81.16 | (2.44) | n.s. |
| SNB (°) | 80.16 | (3.16) | 80.17 | (1.88) | n.s. |
| ANB (°) | 1.54 | (1.51) | 0.89 | (2.69) | n.s. |
| AO-BO (mm) | -5.31 | (1.71) | -5.53 | (1.50) | n.s. |
| <i>Dental pattern</i> | | | | | |
| Occlusal plane (°) | 19.54 | (2.36) | 12.23 | (3.13) | n.s. |
| Upper 1 to SN (°) | 85.15 | (7.17) | 91.29 | (7.13) | n.s. |
| Lower 1 to mandibular plane (°) | 83.87 | (5.47) | 84.86 | (4.24) | n.s. |
| Interincisal angle (°) | 156.01 | (12.23) | 148.07 | (8.76) | n.s. |
| <i>Tongue position</i> | | | | | |
| ∠NSH (°) | 84.83 | (4.74) | 86.87 | (4.32) | n.s. |
| S-H (mm) | 86.06 | (3.08) | 87.73 | (7.21) | n.s. |
| T-P (mm) | 7.15 | (1.80) | 6.25 | (1.87) | n.s. |

n.s. not significant.

Table 2 Mean values and standard deviations (SD) of craniofacial morphology and tongue position in each group post-treatment, and the results of the test of significant differences between the two groups.

| Measurements | YC3 group post-treatment | | Chin cap group post-treatment | | P value |
|---------------------------------|--------------------------|--------|-------------------------------|---------|---------|
| | Mean | SD | Mean | SD | |
| <i>Skeletal pattern</i> | | | | | |
| Facial axis (°) | 86.30 | (3.19) | 87.42 | (2.50) | n.s. |
| Facial depth (°) | 84.78 | (2.93) | 84.88 | (1.97) | n.s. |
| Mandibular plane angle (°) | 29.90 | (3.09) | 28.60 | (2.88) | n.s. |
| Lower face height (°) | 45.78 | (2.78) | 45.02 | (2.76) | n.s. |
| Mandibular arc (°) | 30.29 | (3.03) | 32.62 | (5.83) | n.s. |
| Corpus length (mm) | 59.26 | (3.33) | 59.57 | (3.03) | n.s. |
| Point A to McNamara line (mm) | -1.48 | (2.67) | -0.12 | (2.13) | n.s. |
| Pogonion to McNamara line (mm) | -9.18 | (5.47) | -8.21 | (2.83) | n.s. |
| Gonial angle (°) | 136.23 | (2.96) | 122.04 | (4.76) | * |
| SNA (°) | 81.49 | (4.17) | 82.20 | (2.50) | n.s. |
| SNB (°) | 78.93 | (4.25) | 78.63 | (2.93) | n.s. |
| ANB (°) | 2.58 | (1.73) | 3.32 | (1.56) | n.s. |
| AO-BO (mm) | -3.33 | (2.36) | -2.09 | (2.53) | n.s. |
| <i>Dental pattern</i> | | | | | |
| Occlusal plane (°) | 12.60 | (1.87) | 11.74 | (3.30) | n.s. |
| Upper 1 to SN (°) | 114.10 | (9.57) | 95.78 | (9.10) | * |
| Lower 1 to mandibular plane (°) | 83.58 | (7.54) | 83.70 | (8.91) | n.s. |
| Interincisal angle (°) | 128.39 | (9.88) | 139.38 | (11.10) | * |
| <i>Tongue position</i> | | | | | |
| ∠NSH (°) | 88.02 | (3.55) | 88.78 | (4.44) | n.s. |
| S-H (mm) | 91.55 | (5.33) | 91.25 | (8.23) | n.s. |
| T-P (mm) | 4.22 | (1.50) | 6.70 | (1.93) | * |

n.s. not significant. *P < 0.05.

occur in the labial inclination of the maxillary anterior teeth. Furthermore, the tongue position was elevated post-treatment in the YC3 group. As for treatment effects of chin caps, the use of chin caps for a long period to suppress the antero-inferior growth of the mandible improves the maxillo-mandibular relationship by posteriorly rotating the mandible, and decreasing the mandibular angle (Armstrong, 1961; Thilander, 1965; Lu *et al.*, 1991), however, the results of the present study show that the YC3 not only improves overjet but also changes the position of the hyoid bone by elevating the tongue. This new position is retained through re-education. From the perspective of these changes in tongue position, it is speculated that the YC3 has functional effects on the skeletal system during the mid-growth period. However, further evaluation after long-term follow-up is necessary.

Conclusions

The findings of the present study suggest that the treatment effects of the YC3 are not only an improvement in overjet, but also a change in tongue position from an antero-inferior to a postero-superior position in anterior crossbite subjects as a result of elevation of the tongue. The results also indicate that the YC3 has functional effects on the skeletal system during the mid-growth period.

Address for correspondence

I Nakajima
Department of Pediatric Dentistry
Nihon University School of Dentistry
1-8-13 Kanda Surugadai
Chiyoda-ku
Tokyo 101-8310
Japan
E-mail: onodera-k@dent.nihon-u.ac.jp

Acknowledgement

We are grateful to the members of the Department of Pediatric Dentistry Nihon University School of Dentistry for assisting in the accomplishment of this paper.

References

- Adamidis I P, Spyropoulos M N 1992 Hyoid bone position and orientation in Class III malocclusions. *American Journal of Orthodontics and Dentofacial Orthopedics* 101: 308–312
- Agronin K J, Kokich V G 1987 Displacement of the glenoid fossa: a cephalometric evaluation of growth during treatment. *American Journal of Orthodontics and Dentofacial Orthopedics* 91: 42–48
- Armstrong C J 1961 A clinical evaluation of the chin cap. *Australian Dental Journal* 6: 338–346
- Bandy H E 1969 Tongue volume and the mandibular dentition. *American Journal of Orthodontics* 56: 134–142
- Downs W B 1948 Variations in facial relationship: their significance in treatment and prognosis. *American Journal of Orthodontics and Oral Surgery* 34: 812–840
- Durgo C A, Brodie A G 1962 Growth behavior of the hyoid bone. *Angle Orthodontist* 32: 193–204
- Eifert D F 1960 A roentgenographic cephalometric study of the tongue. *American Journal of Orthodontics* 46: 226–227
- Higuchi N 1998 A study on maxillofacial features of young children with anterior cross-bite. An examination of the facial patterns using Ricketts' method of analysis. *Nihon University Dental Journal* 72: 170–180
- Ichiishi K, Kitamura M, Masumori M, Kikuchi M, Dohi M, Akasaka M 1997 Recent situation concerning dental disease and nutritive condition of young children. *Japanese Journal of Pediatric Dentistry* 35: 821–828
- Imai T, Watanabe F, Nakamura S 1990 A clinical study on the prevalence of temporomandibular joint dysfunction in orthodontic patients. *Dentistry in Japan* 27: 97–99
- Jacobson A 1976 Application of the Wits appraisal. *American Journal of Orthodontics* 70: 179–189
- Korkhaus G 1957 Disturbances in the development of the upper jaw and the middle face. *American Journal of Orthodontics* 43: 848–868
- Lo C H 2001 The study on the influence of the anterior cross-bite on the masticatory muscle activities in deciduous dentition. *Nihon University Dental Journal* 75: 393–402
- Lu Y C, Tanne K, Sakuda M 1991 The effects of orthopedic treatment with chin cap on craniofacial growth in adolescent Class III patients. *Journal of Osaka University Dental School* 316: 85–94
- McNamara Jr J A 1981a Components of Class II malocclusion in children 8–10 years of age. *Angle Orthodontist* 51: 177–202
- McNamara Jr J A 1981b Influence of respiratory pattern on craniofacial growth. *Angle Orthodontist* 51: 269–300
- Mitani H, Sakamoto T 1984 Chin cap force to a growing mandible. Long-term clinical report. *Angle Orthodontist* 54: 93–122
- Moss J P 1975 Function-fact or fiction? *American Journal of Orthodontics* 67: 625–646
- Ohki S, Fujita K, Sato M 1990 Hyoid bone position and facial morphology in adults with normal occlusion. *Journal of the Kyushu Dental Society* 44: 260–270
- Ricketts R M 1960 A foundation for cephalometric communication. *American Journal of Orthodontics* 46: 330–357
- Ricketts R M 1972 The value of cephalometrics and computerized technology. *Angle Orthodontist* 42: 179–199
- Rogers A P 1918 Muscle training and its relation to orthodontia. *International Journal of Orthodontics* 4: 555–577
- Sakata T 2001 A study on the relationship between the position of the hyoid bone in subjects with reversed occlusion and maxillofacial shape in childhood. *Nihon University Dental Journal* 75: 28–37
- Thilander B 1965 Chin-cap treatment for Angle Class III malocclusion: a longitudinal study. *Transaction of European Orthodontic Society*, pp. 311–327
- Uchiyama T 2000 The relationship between the position of the hyoid bone and the maxillofacial morphology in children. *Nihon University Dental Journal* 74: 146–153
- Yanagisawa M 1985 Study of treatment of functional orthodontic appliances in anterior cross-bite (1). *Journal of Japan Orthodontic Society* 44: 734–735

Copyright of European Journal of Orthodontics is the property of Oxford University Press / UK and its content may not be copied or emailed to multiple sites or posted to a listserv without the copyright holder's express written permission. However, users may print, download, or email articles for individual use.